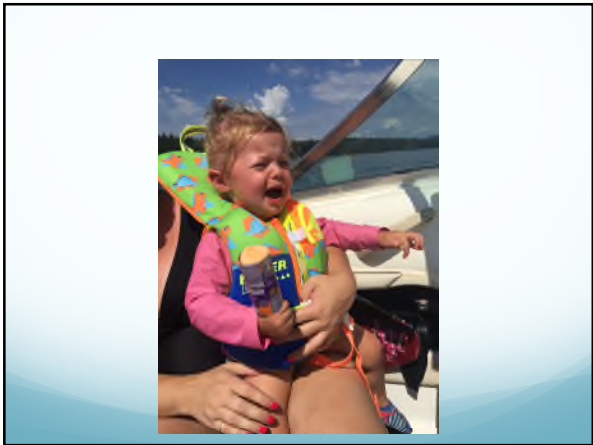



Abdominal Pain

Curtis Brown, M.D FACEP





Rosetta Stone

- A granodiorite stele, found in 1799, inscribed with three versions of a decree issued at Memphis, Egypt in 196 BC.
- The top and middle texts are in Ancient Egyptian using hieroglyphic script and Demotic script, while the bottom is in Ancient Greek.
- It is the key to deciphering Egyptian hieroglyphs.

Pediatric Abdominal Pain

- HPI
 - Length of Time of SXS
 - Description, Location, Timing, Frequency of Pain
 - Level of Activity
 - Associated Symptoms
 - fever, vomiting, diarrhea, hydration status, diet
 - ?non-GI causes?

- Patient History
 - Past Medical History
 - Medications
 - Surgical History
 - Social History

Physical Exam

- Infant/Toddler
 - Older kids
 - **RED FLAGS**
 - Lethargy/Listlessness Peritoneal signs
 - Inconsolable Crying Abnormal Fontanelle
 - Intractable vomiting Nuchal Rigidity/petechiae
- PATTERNS OF INJURY

TAKE DOWN THE DIAPER

and
LOOK

Differential Diagnosis

- APPY
- APPY
- APPY
- Then all the other stuff

THE OTHER STUFF

- Constipation
- Gastroenteritis
- DKA
- Toxic ingestions
- Metabolic disorders
- Referred Pain

uti, pneumonia, asthma, strep throat, head injury, non-accidental trauma, HSP, back pain, stress, sexual abuse

THE BAD STUFF

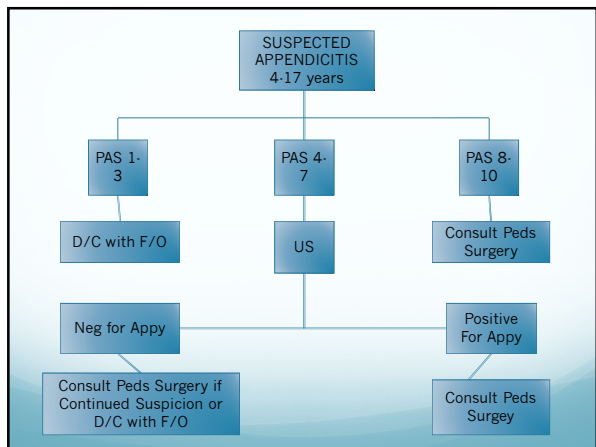
- Malrotation with Volvulus
- Intussusception
- Hirschsprung disease with Acute Obstruction
- Blunt Trauma
- Adhesions with Obstruction/Perforation
- Incarcerated Hernia
- Gonadal Torsion
- Cholecystitis/Pancreatitis
- Foreign Body

APPENDICITIS

- 8% of children who present with abdominal pain
- Infants rare but missed often until PERFORATION
- Age 2-5 < 50% have RLQ pain
- Age 5-10 +80% + McBurney's sign

PEDIATRIC APENDIX SCORE

- Migration of Pain 1
- Anorexia 1
- Nausea/Vomiting 1
- RLQ Tenderness 2
- Coughing/Hopping/Percussion Pain 2
- Fever 1
- Leukocytosis 1
- Left Shift on WBC diff. 1



CASE # 1

- 6 month old Female
- 3 days of vomiting, crying, fever, abdominal pain

- What are your thoughts?

hint: trick question

CASE #2

- 5 years old
- 2 days of vomiting, abd pain, fever to 101F, does not want to eat his favorite food of boiled spinach and chick pees in a chocolate sauce
- Pain started near belly button and now RLQ
- When he hops he holds his RLQ and says it really hurts and why did you make him jump up and down

SCORE ?

What is your next move?

CASE#3

- 8 years old
- 2 days of generalized abdominal pain
- Mom states he felt hot but does not have a thermometer at home, his temp in ED is 100.5F. He ate some oatmeal this am but he vomited after and now is not hungry. On exam there is tenderness in the suprapubic and RLQ.
- What do you want to do?

Case#3

- CBC with Diff.
- BMP
- UA
- +/- CXR KUB

CASE#3

ULTRASOUND

What if + ?

What if - ?

WHEN DO WE USE CT?

Discharge Instructions

- F/O 12 – 24 hours by PCP or ED
- Return immediately for fever, vomiting, change in pain or pain in RLQ, not taking PO fluids, or any change in condition or concerns.
- Appendicitis is not always easy to diagnose and can masquerade as many things.
