

RADIOLOGY 101

Curtis Brown, M.D. FACEP

1



2



3



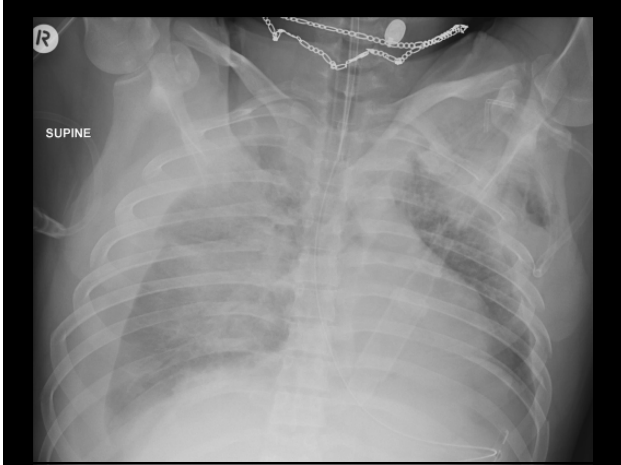
4



5



6

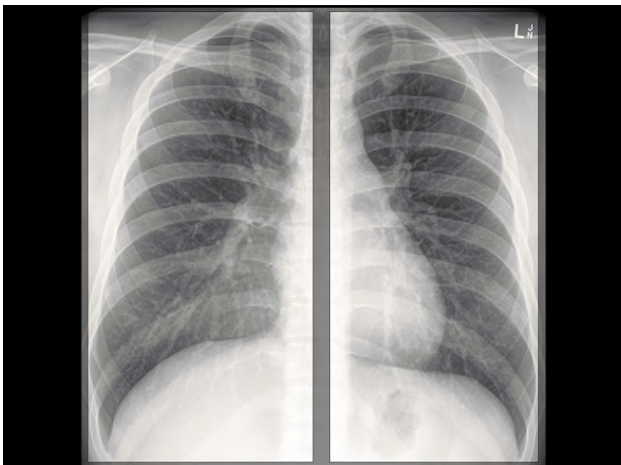


7

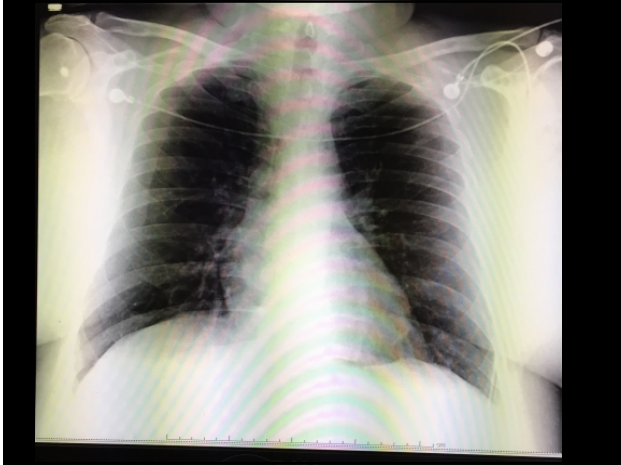
CHEST X-RAY PIER

- Position upright, PA, lateral, supine
- Inspiration count ribs 10-11th rib=good breath
- Exposure over/under
- Rotation check clavicles

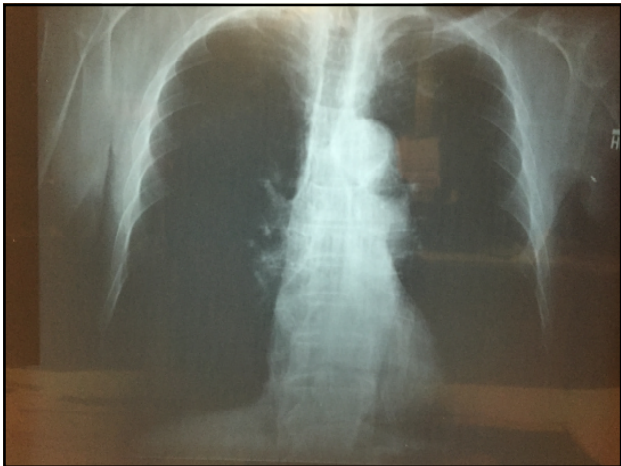
8



9



10

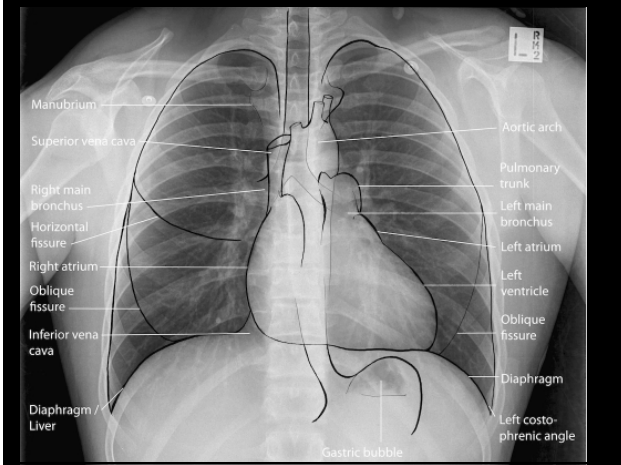


11

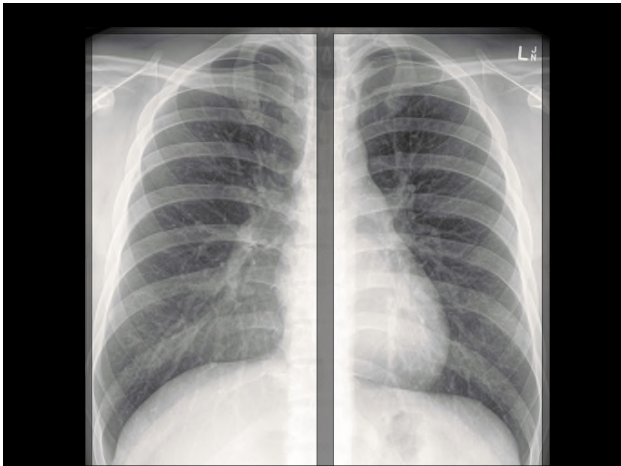
CHEST X-RAY

- Airway
- Bones/Breast shadows
- Cardiac
- Diaphragm/Digestive tract
- Edges
- Fields/Failure
- Gastric Bubble
- Hilar Region

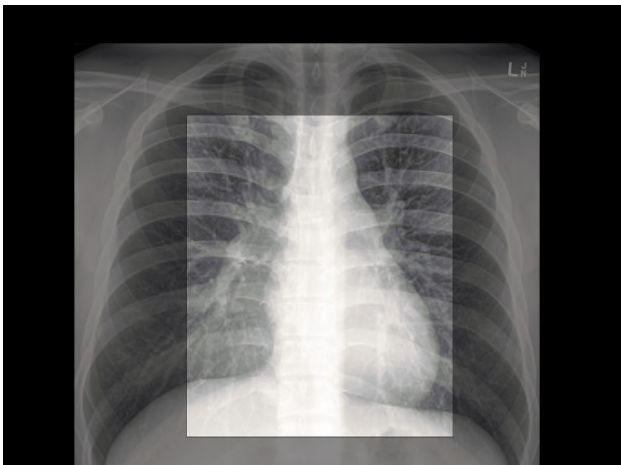
12



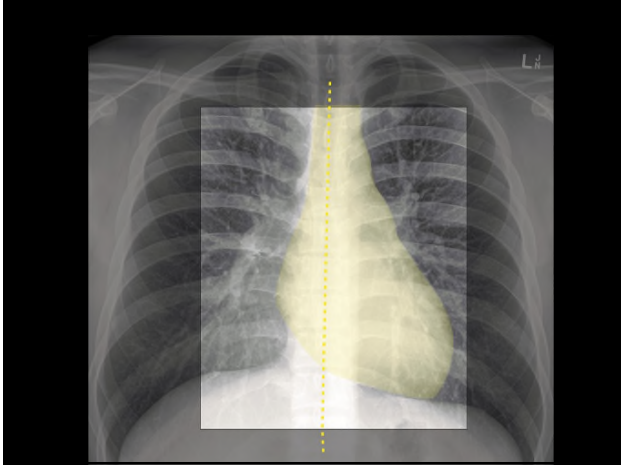
13



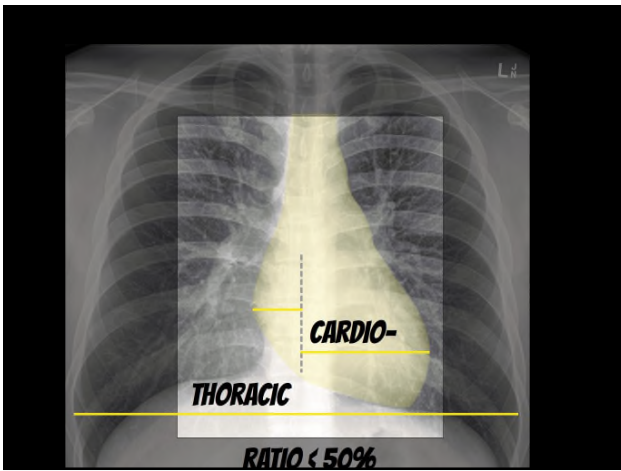
14



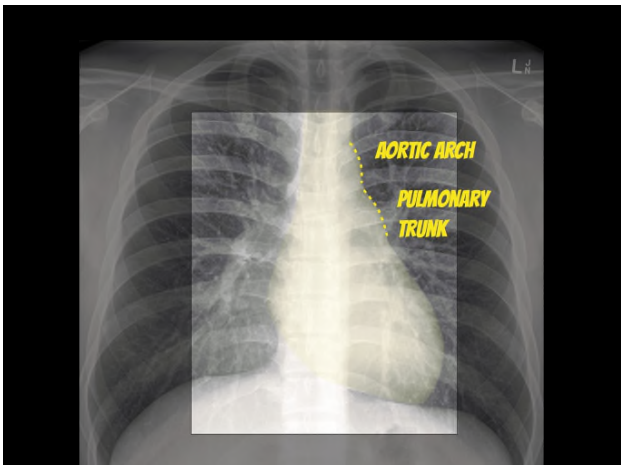
15



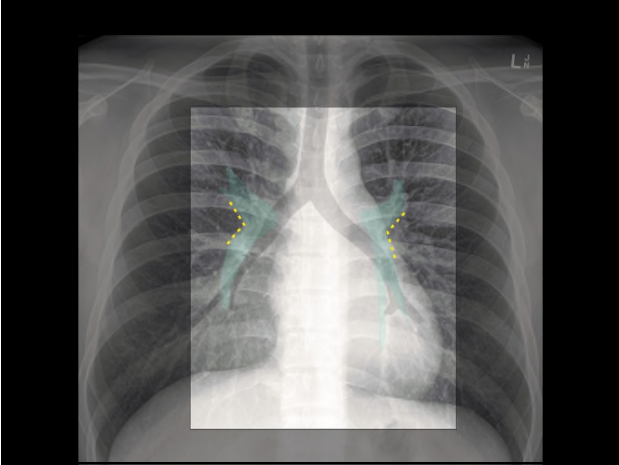
16



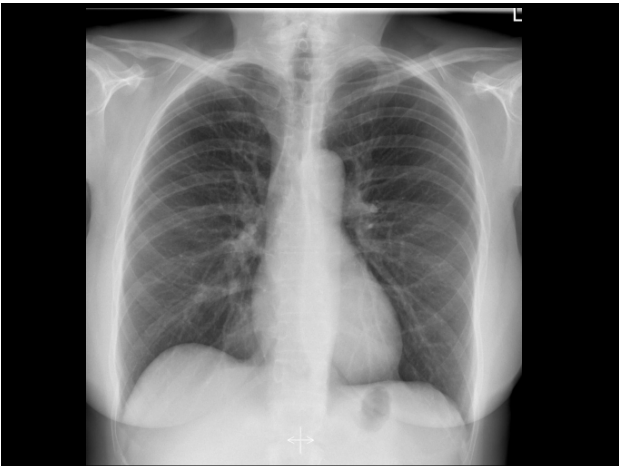17



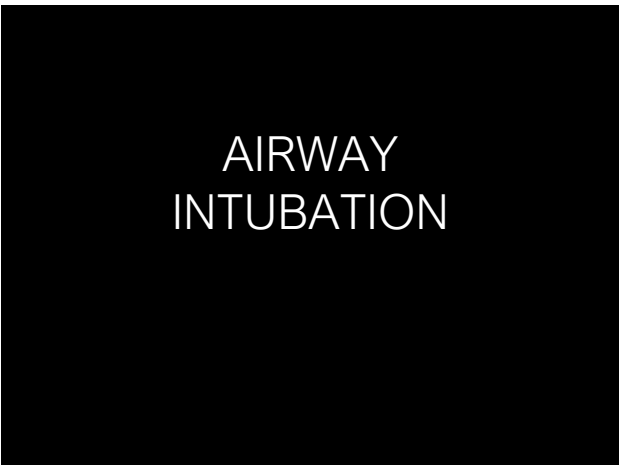
18



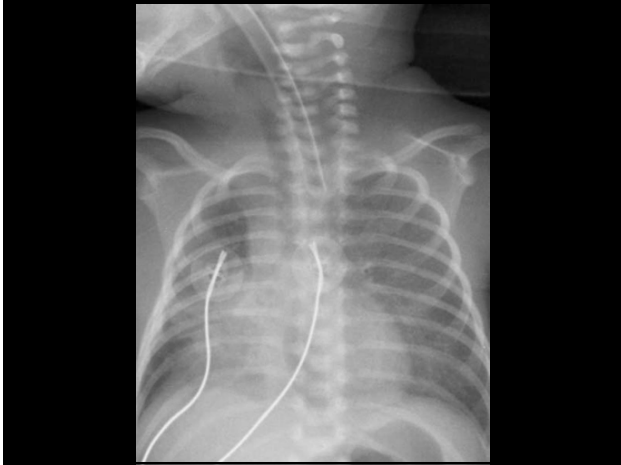
19



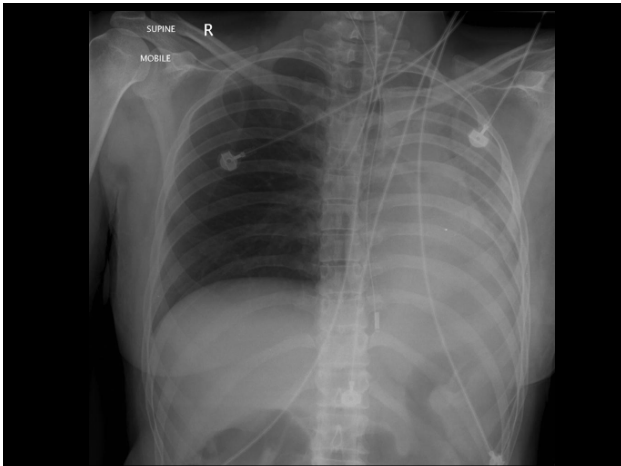
20



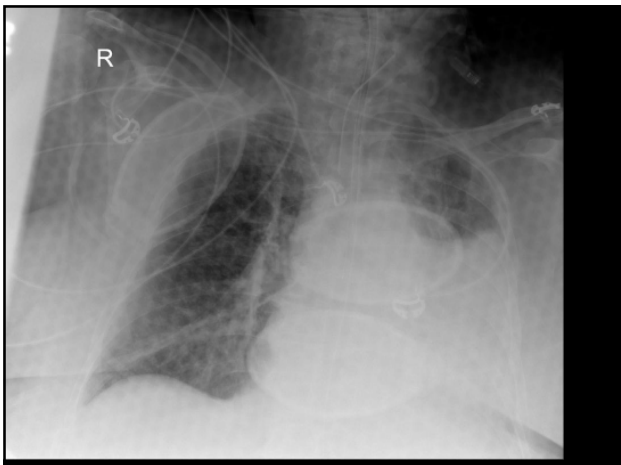21



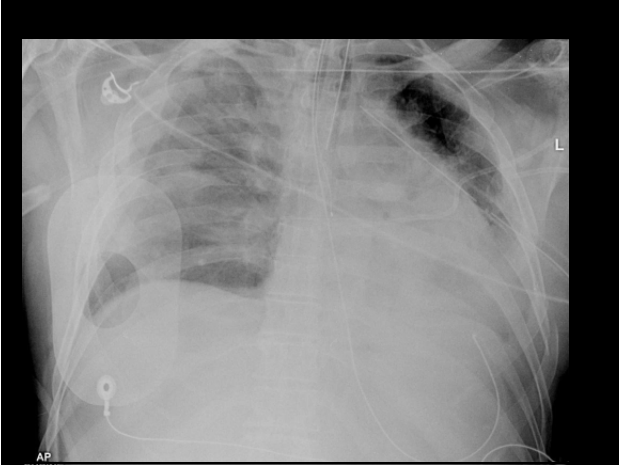
22




23



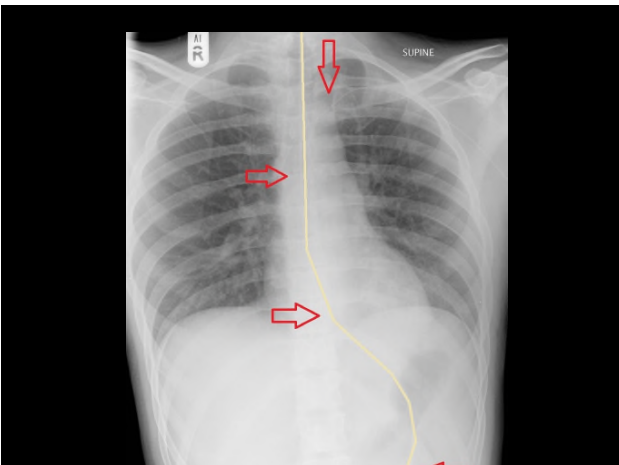
24



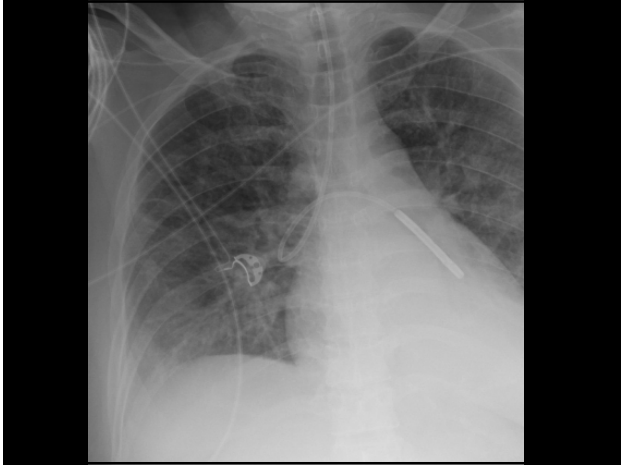25



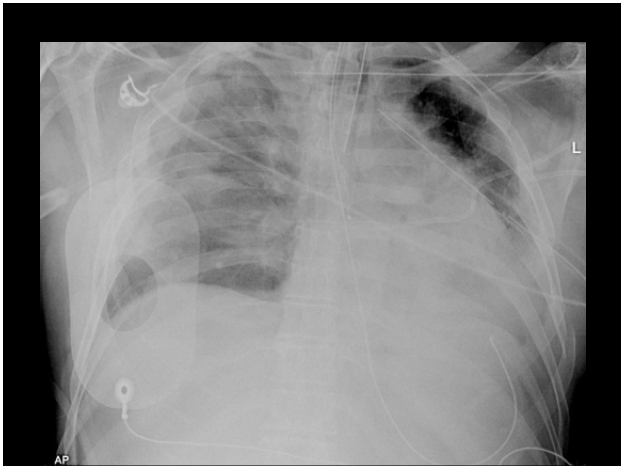26



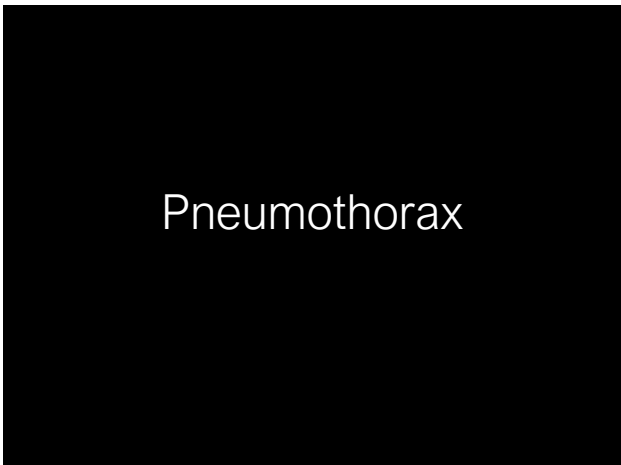
27



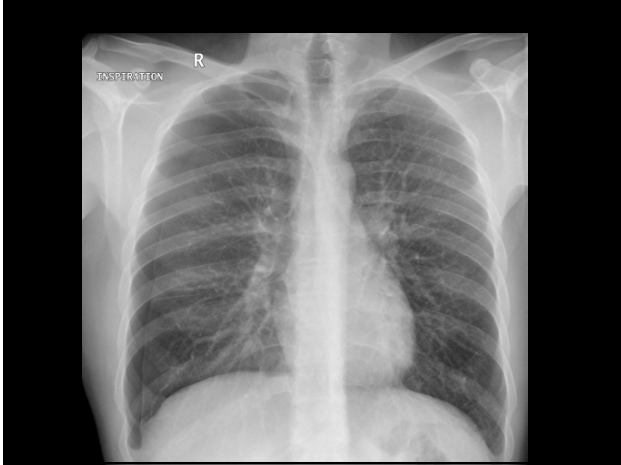
28



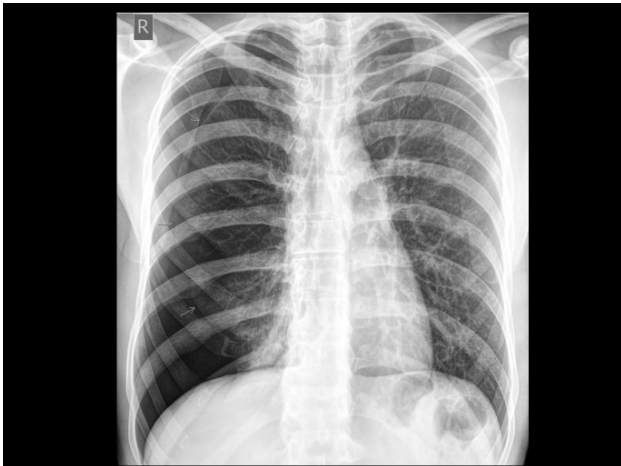29



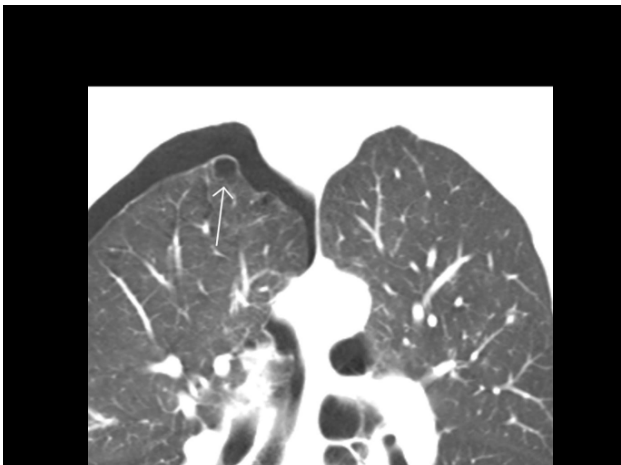
30



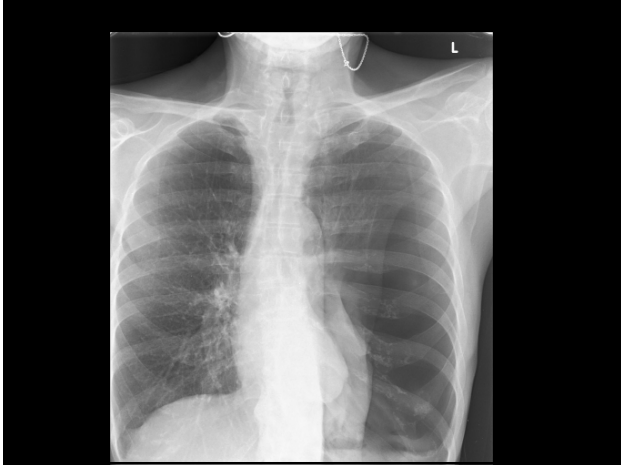31



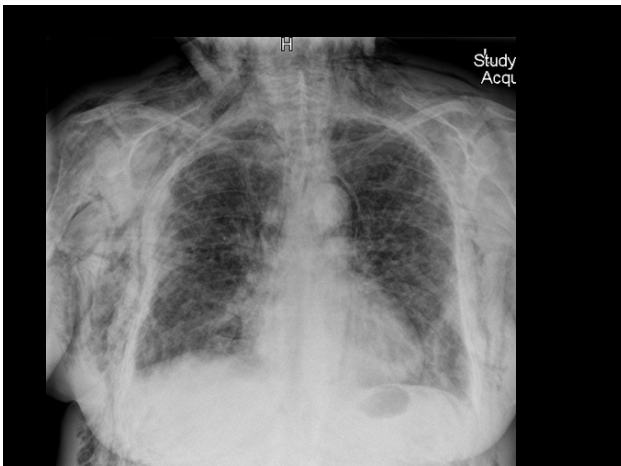32



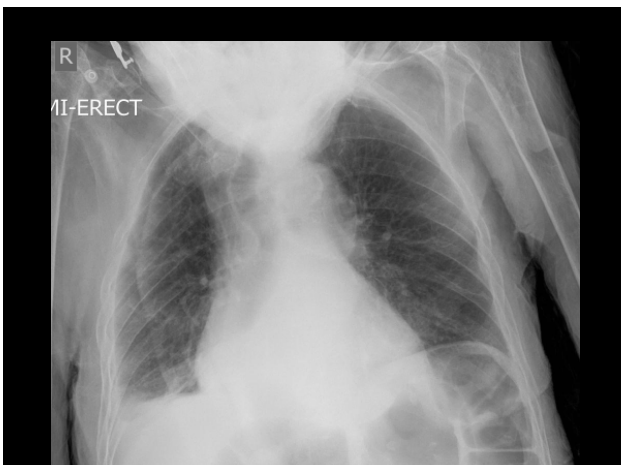33



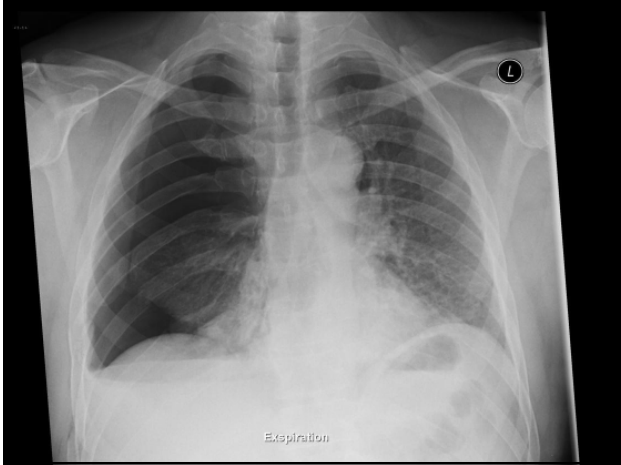34



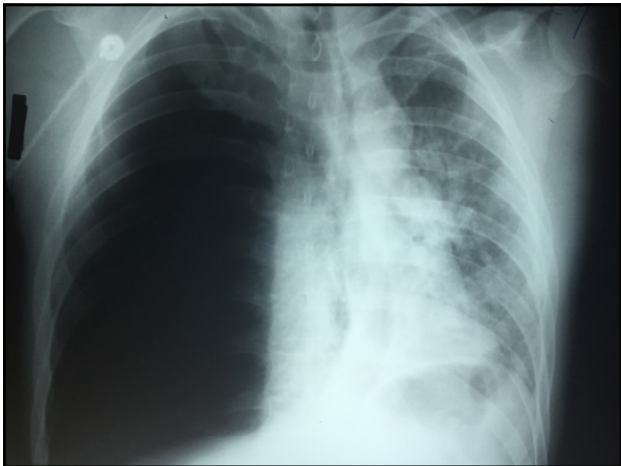
35



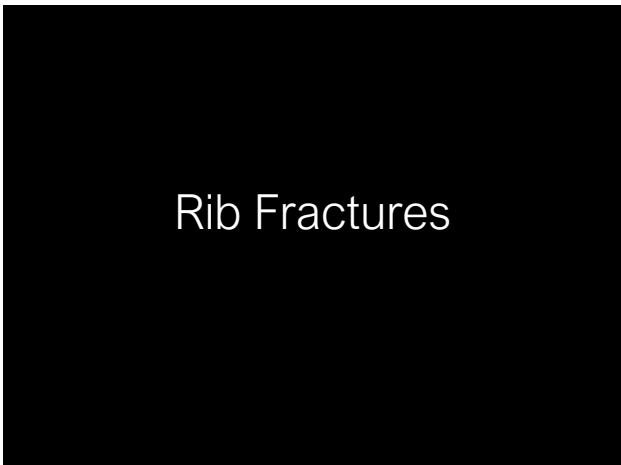36



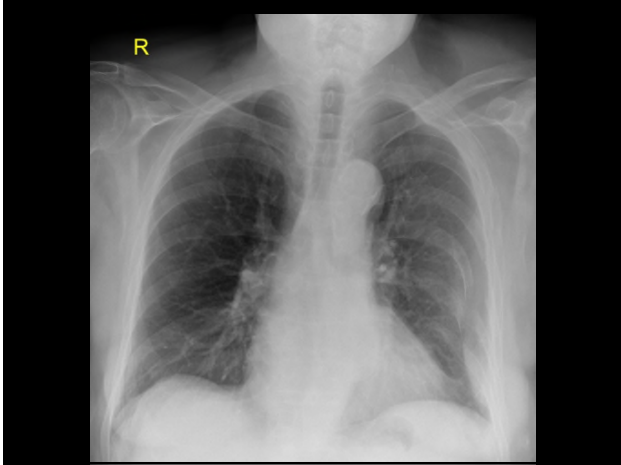
37



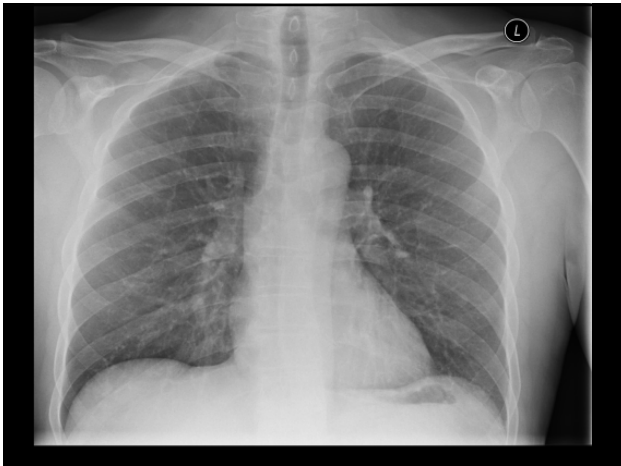
38



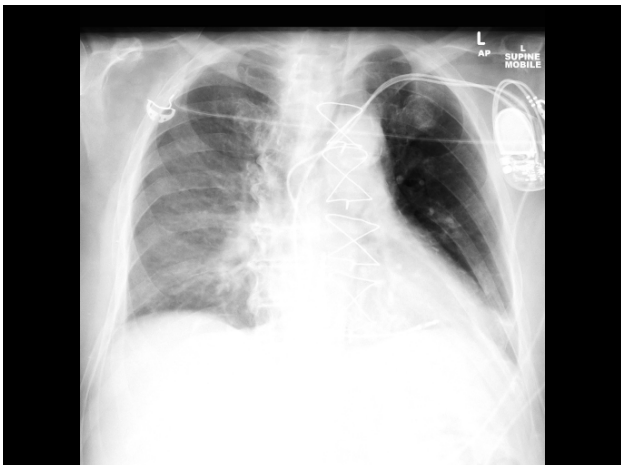
39



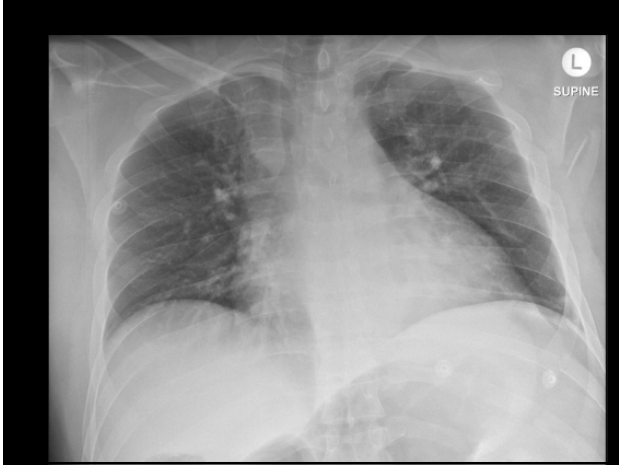40



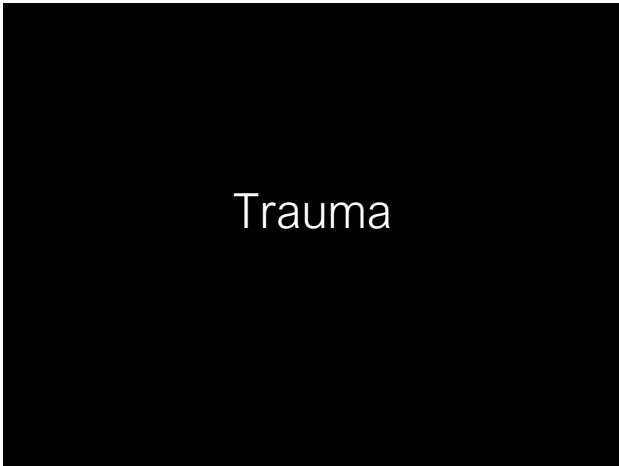41



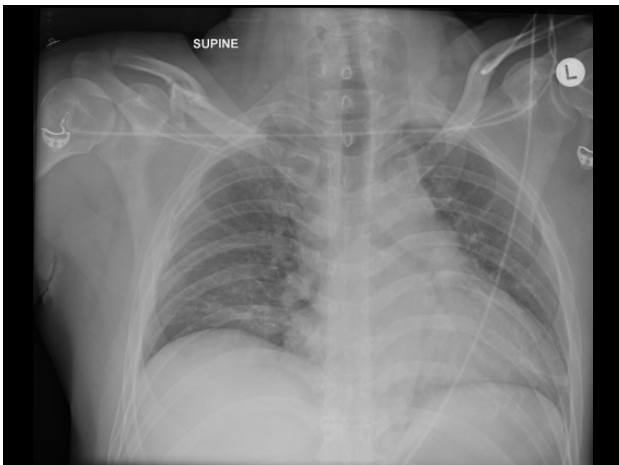
42



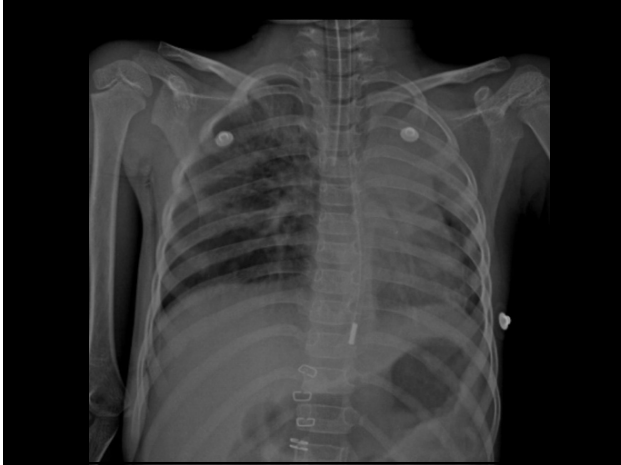43



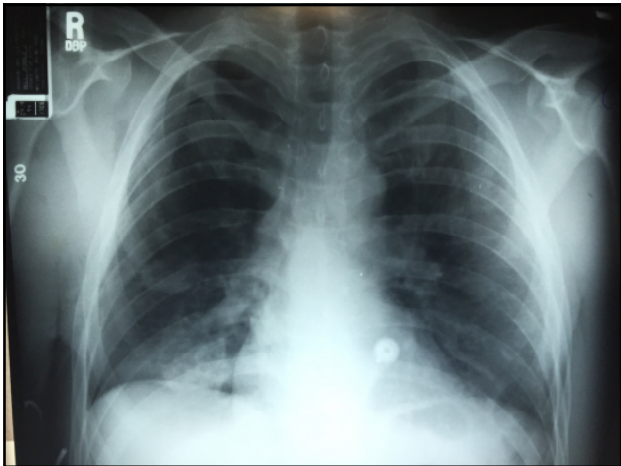
44



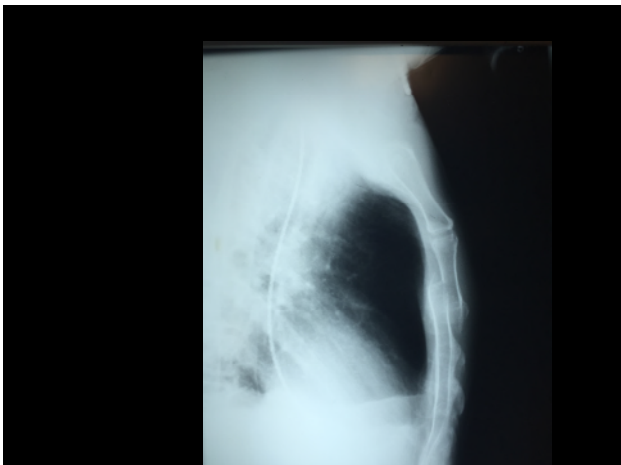
45



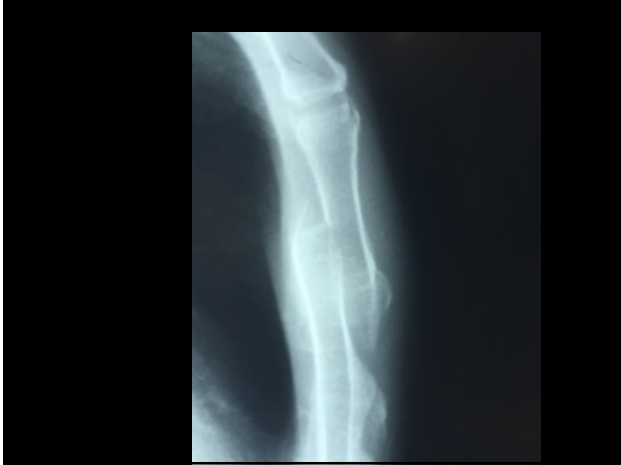
46



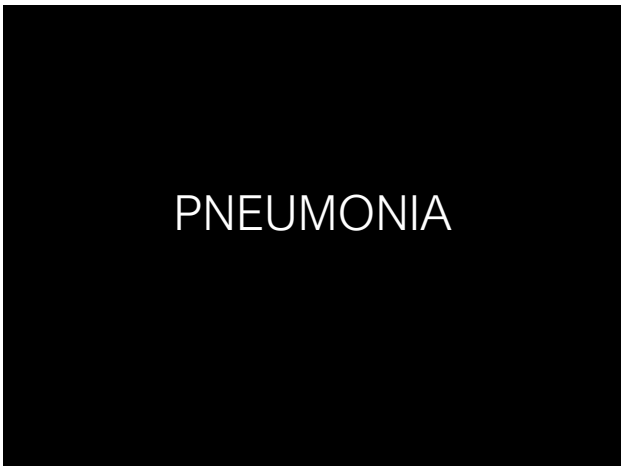
47



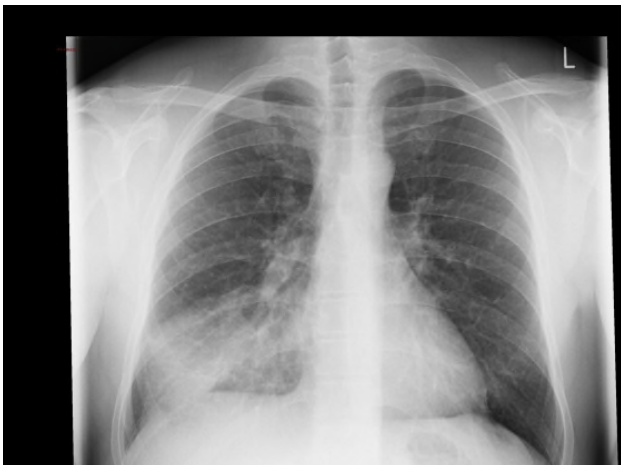48



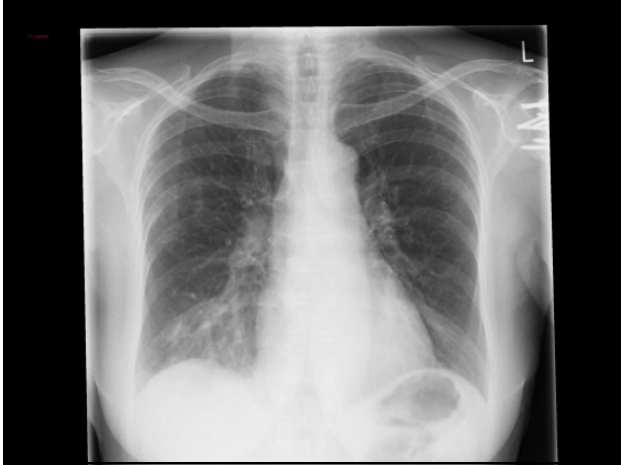49



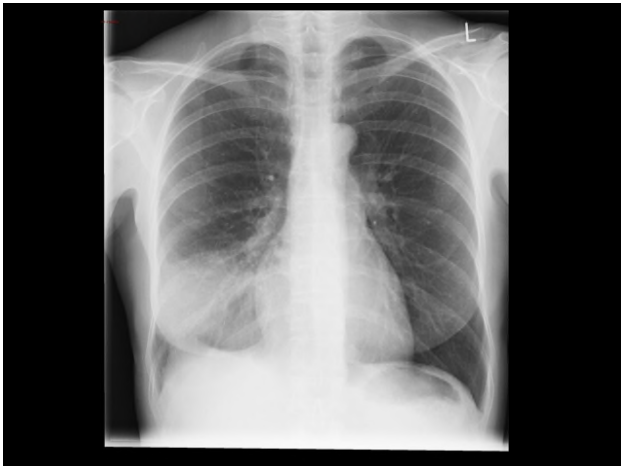50



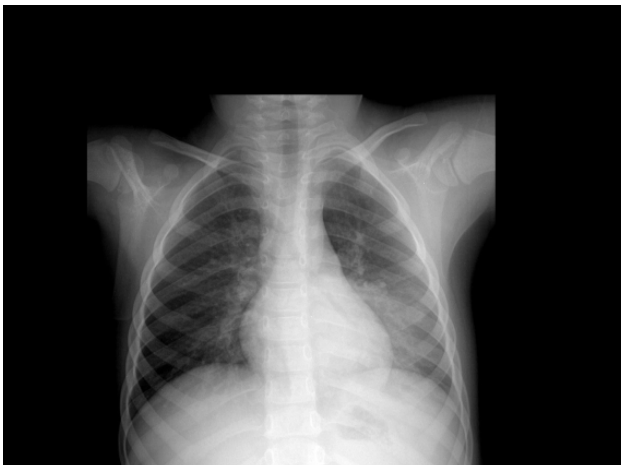51



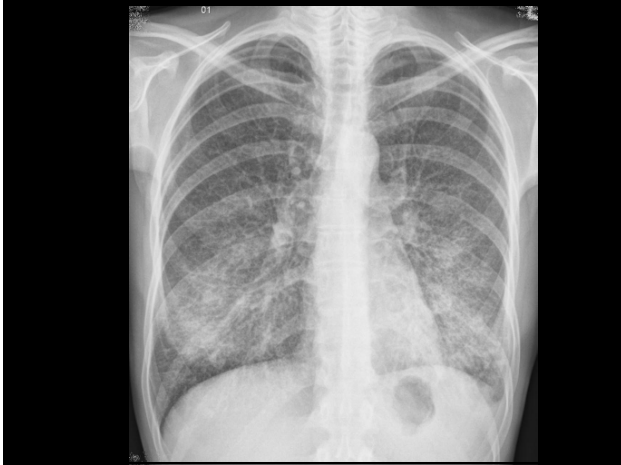52



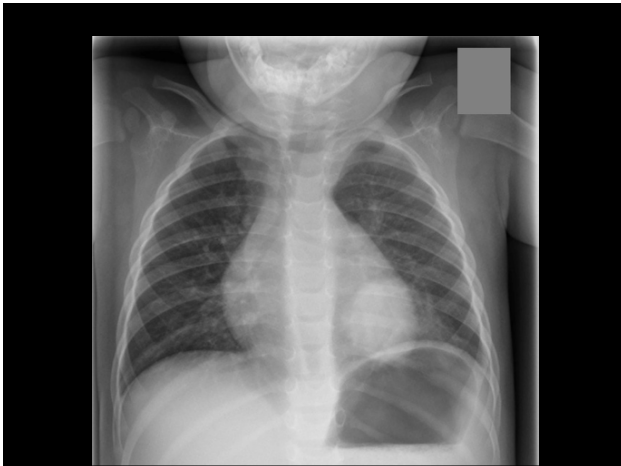
53



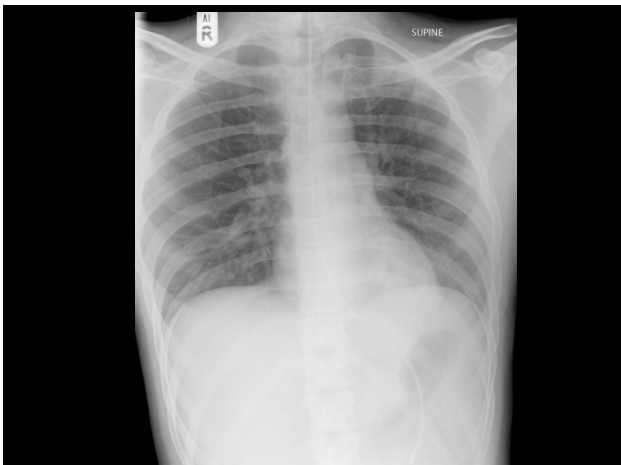54



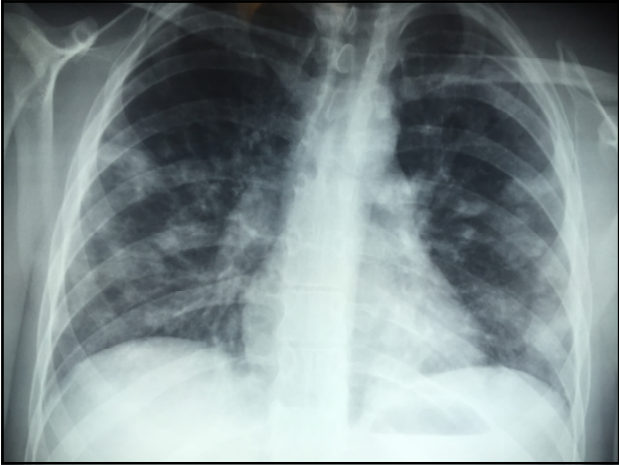
55



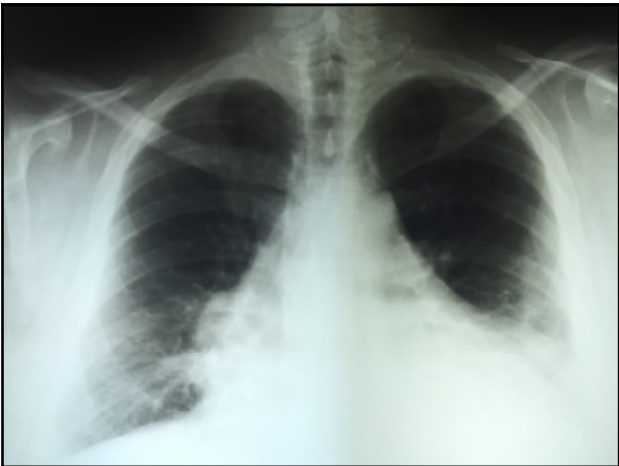56



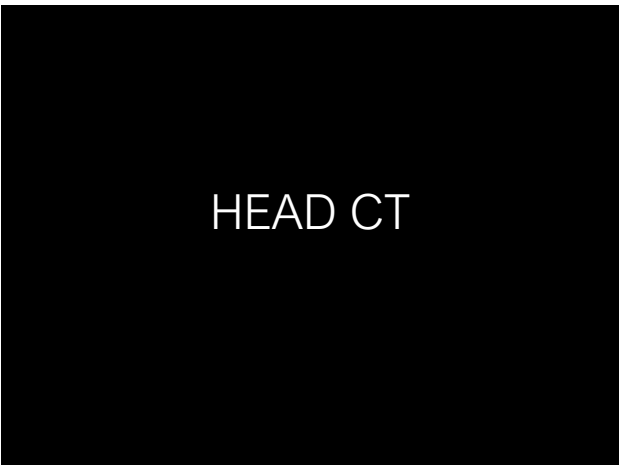57



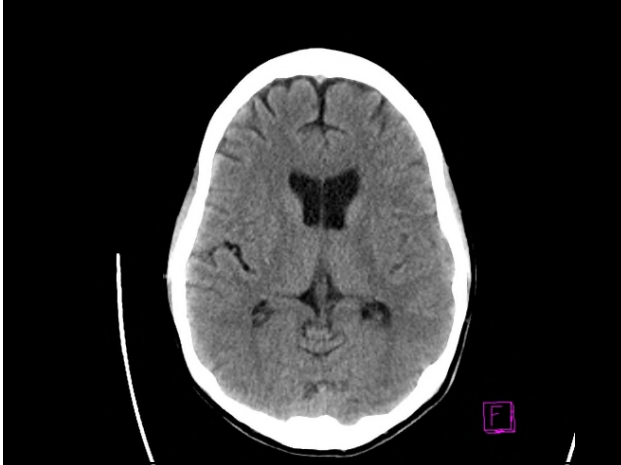
58



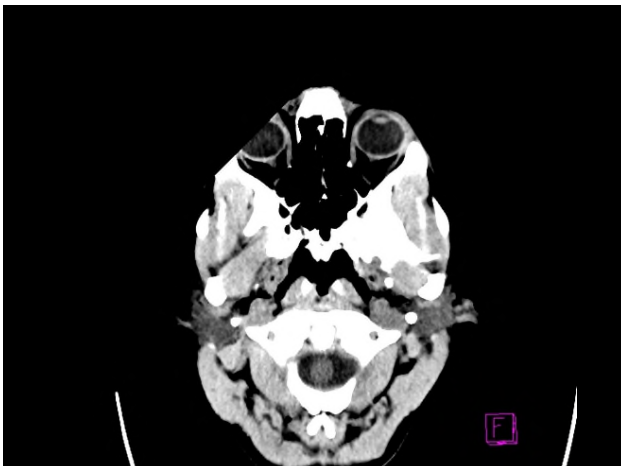
59



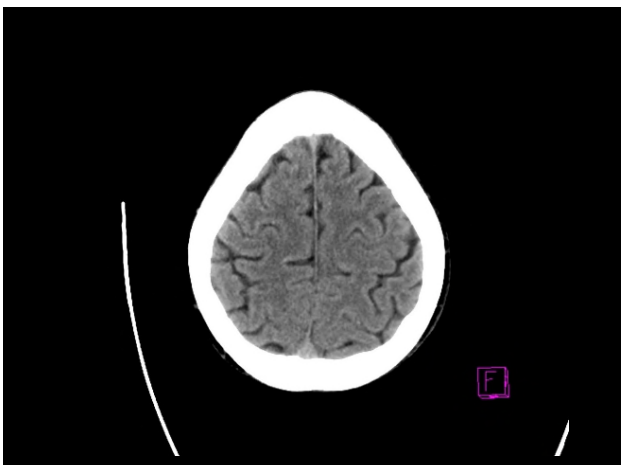
60



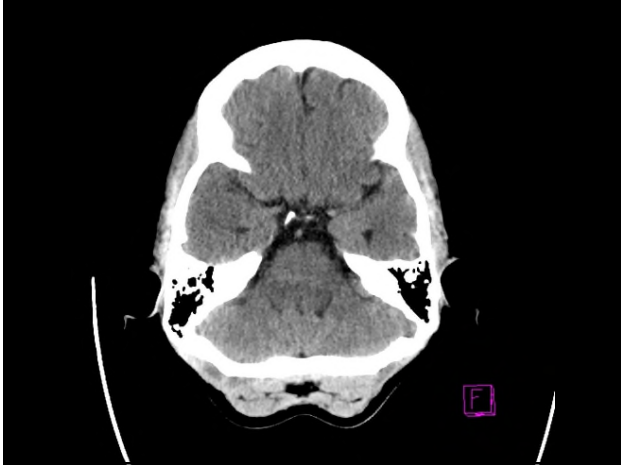
61



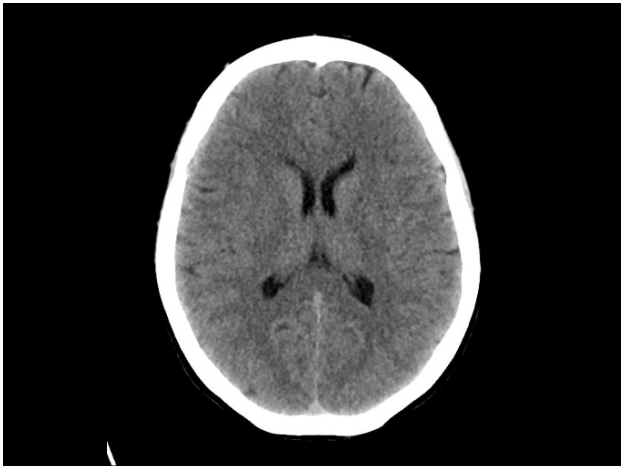62



63



64

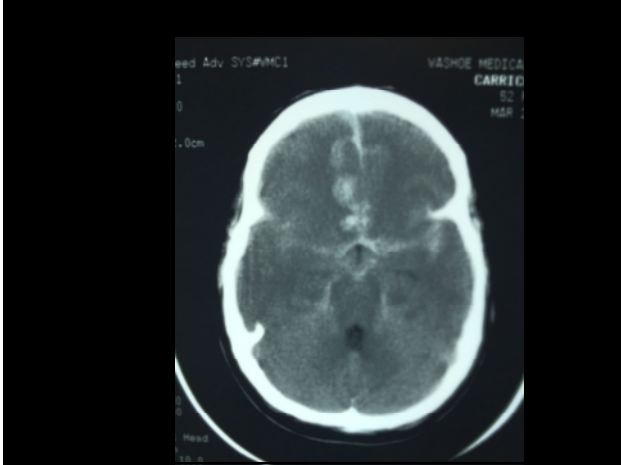


65

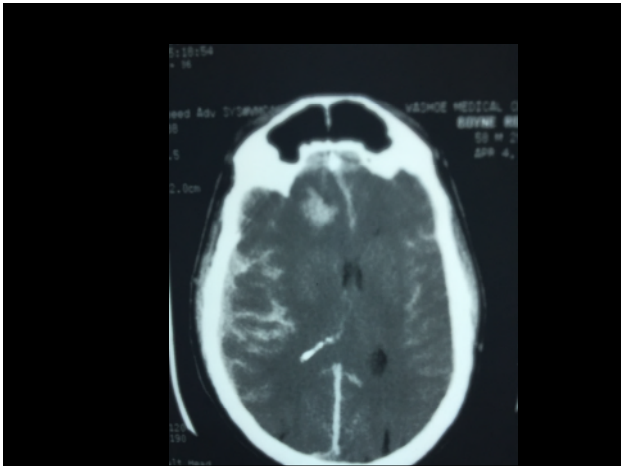
Blood Can Be Very Bad

- Blood
- Cisterns
- Brain
- Ventricals
- Bone

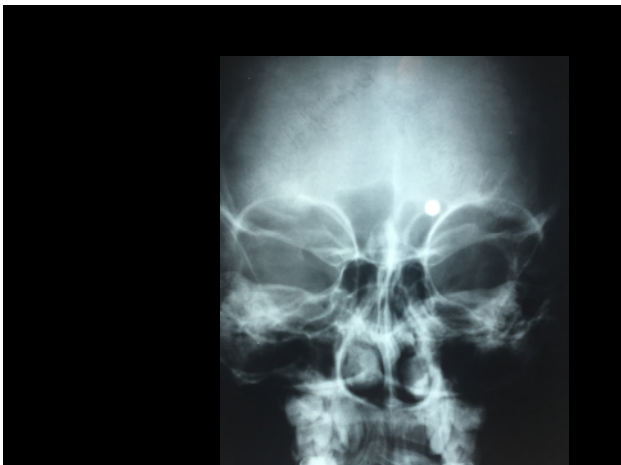
66



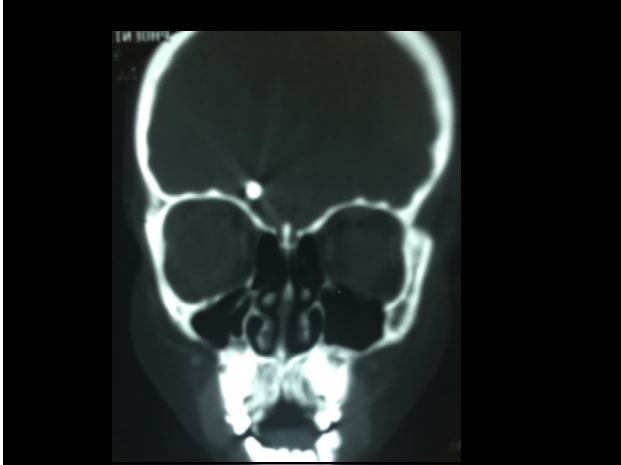67



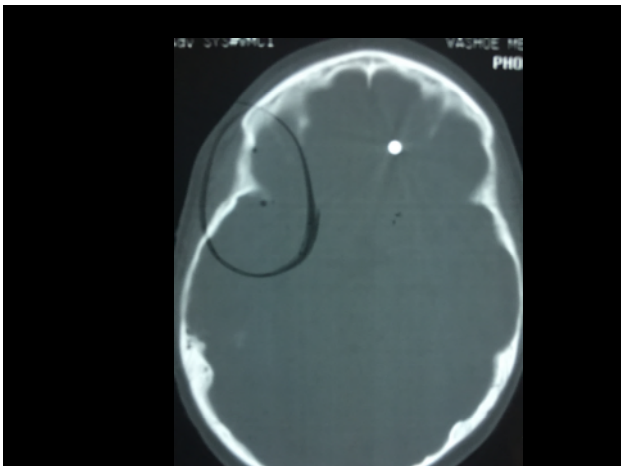
68



69



70



71

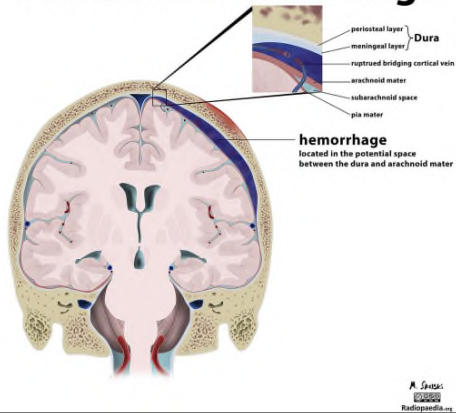


72

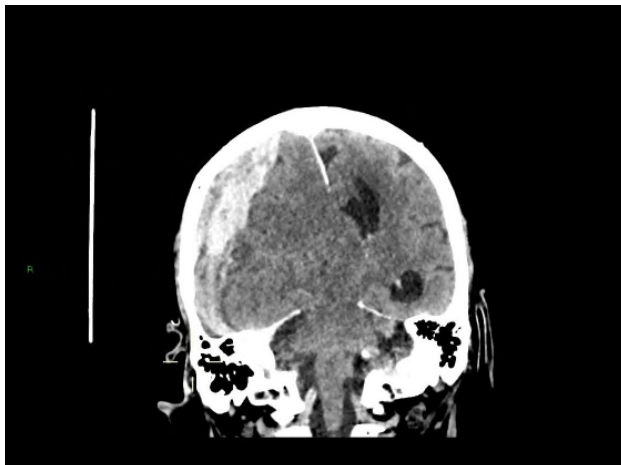
SUBDURAL

73

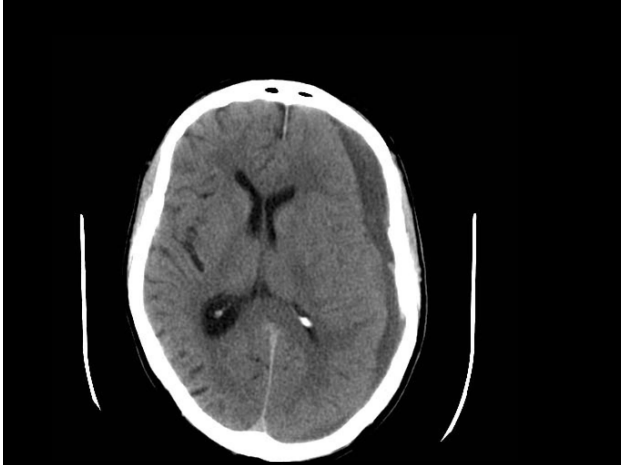Subdural hemorrhage



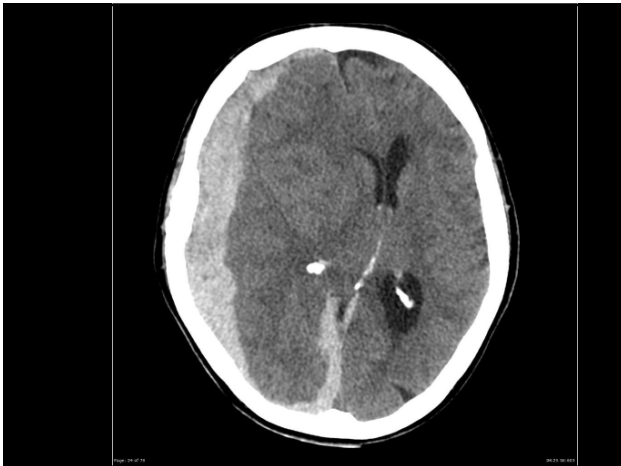
74



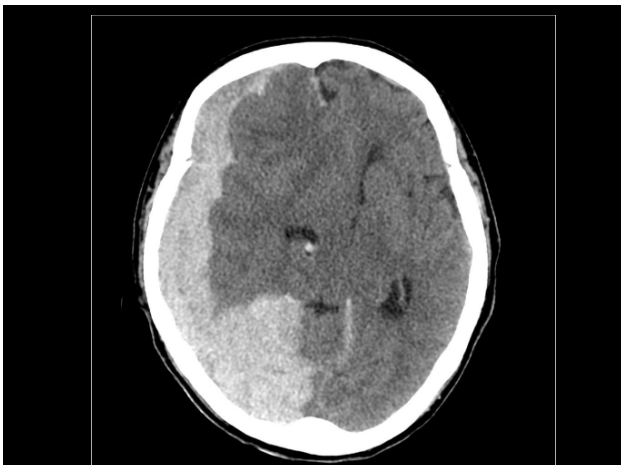
75



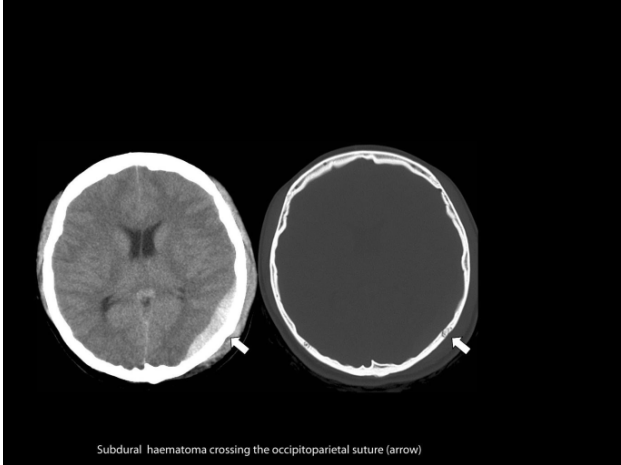
76



77

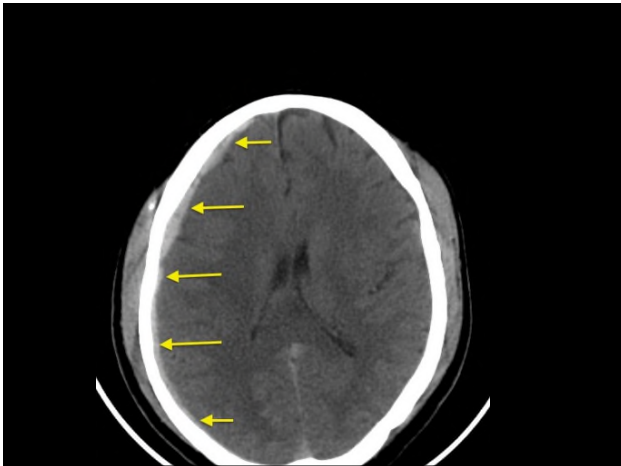


78

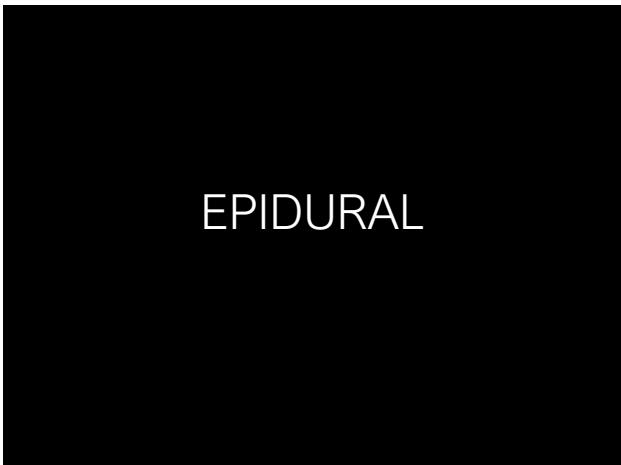


Subdural haematoma crossing the occipitoparietal suture (arrow)

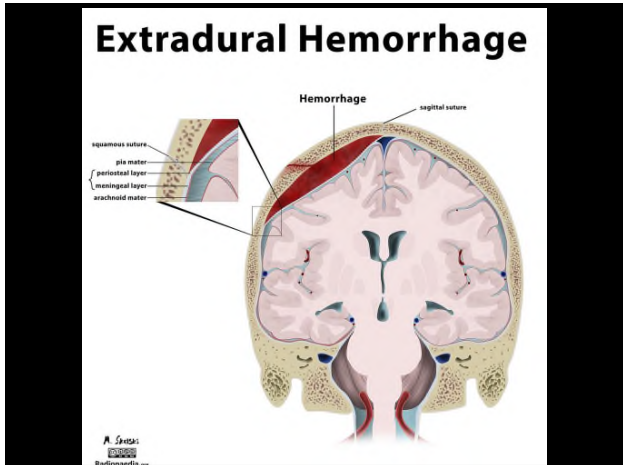
79



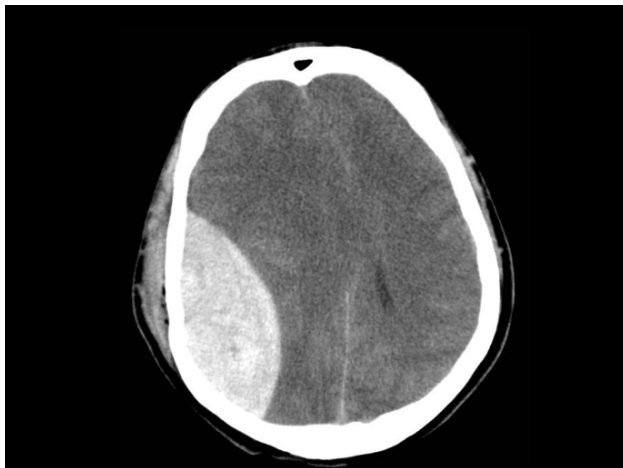80



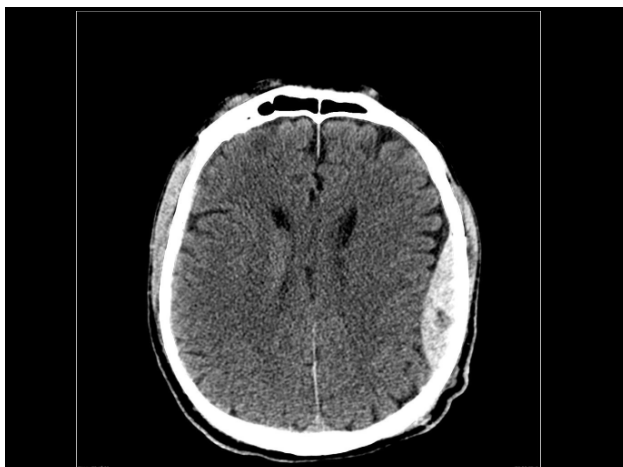81



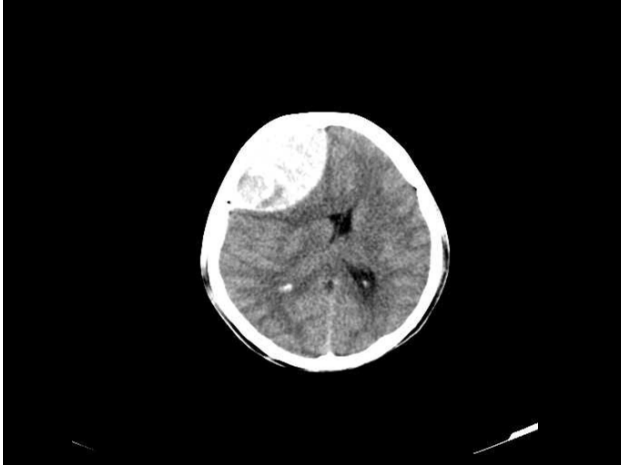82



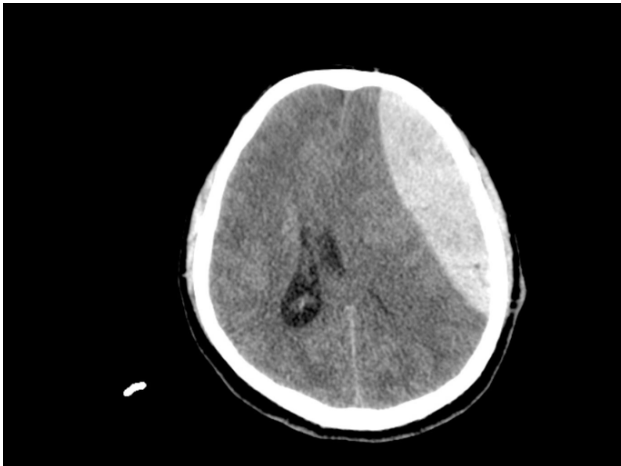
83



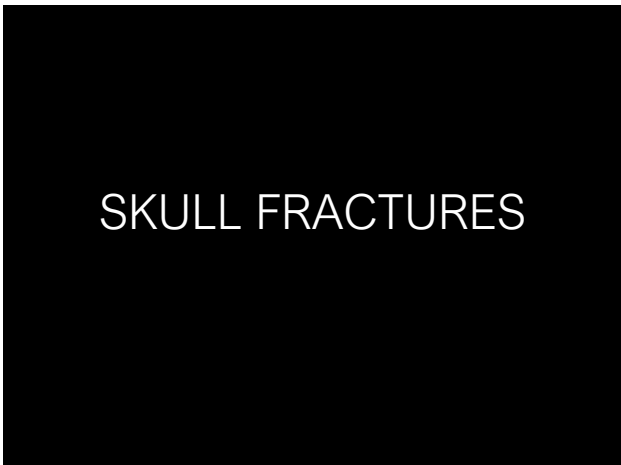84



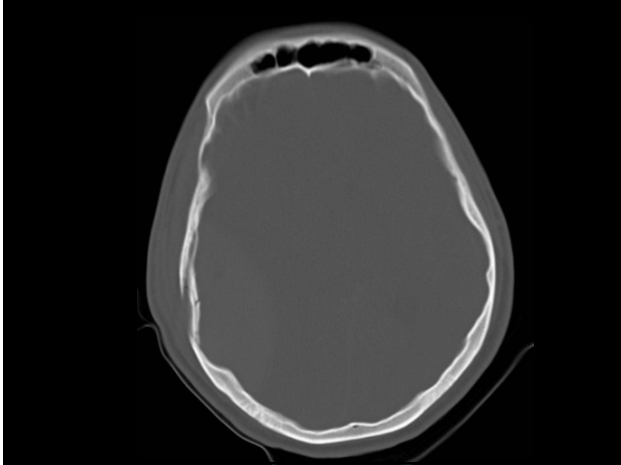
85



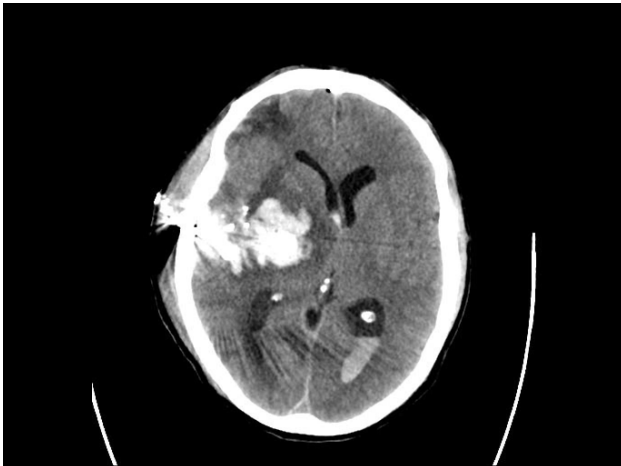86



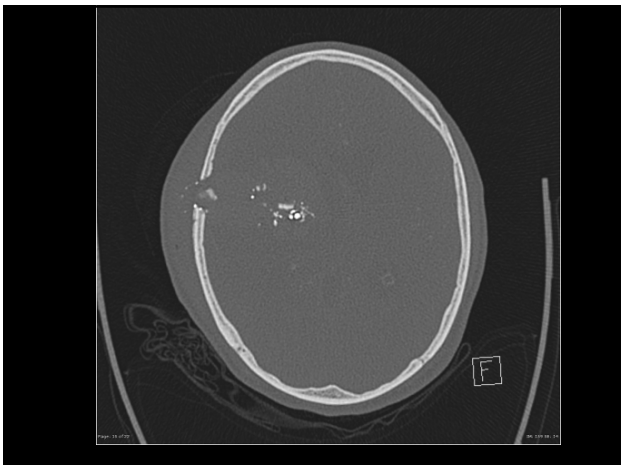
87



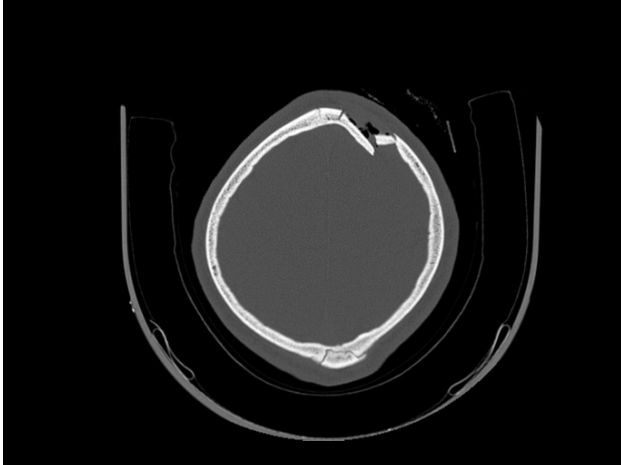
88



89



90



91

CERVICAL SPINE

92

Space between odontoid and arch of atlas can be up to 5 mm in children c.f. 2.5 mm in adults.

Soft tissues closely applied to vertebral bodies from C2–C5 in adults. Varies widely with phase of respiration in infants. > 7 mm opposite C2 is abnormal.

Anterior wedging of vertebral bodies is a developmental finding.

Absent lordosis is a frequent normal finding.

Superior and inferior facets of apophyseal joints are exactly congruous.

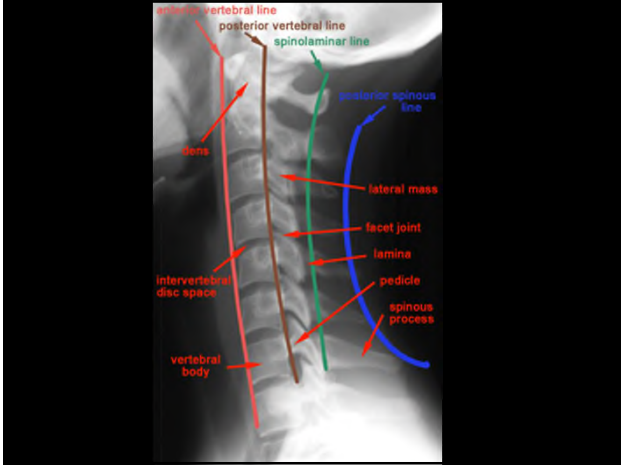
C7/T1 junction must be visualised.

The four lines shown in the figure are:

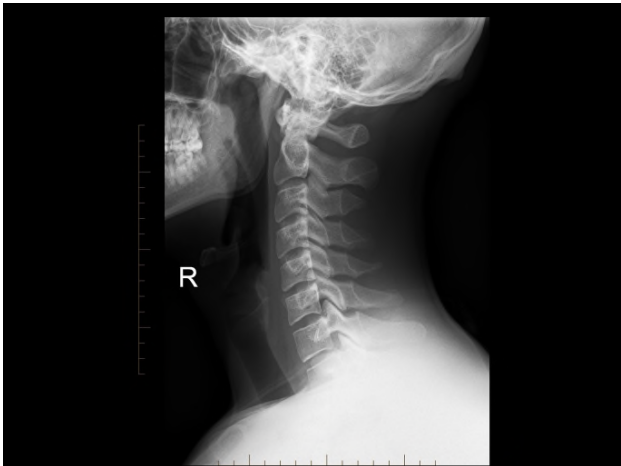1. Anterior vertebral line.
2. Posterior vertebral line (anterior wall of the spinal canal).
3. Facet line.
4. Spino-laminar line (posterior wall of spinal canal).

All 4 lines should be smooth with no steps or angulation. The spinolaminar line remains smooth even in the presence of pseudosubluxation.

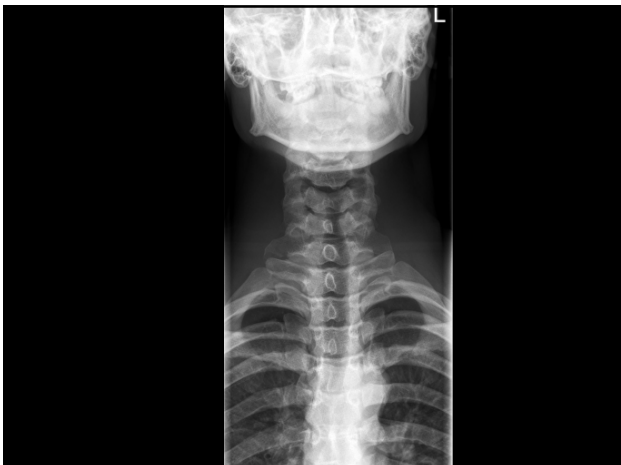93



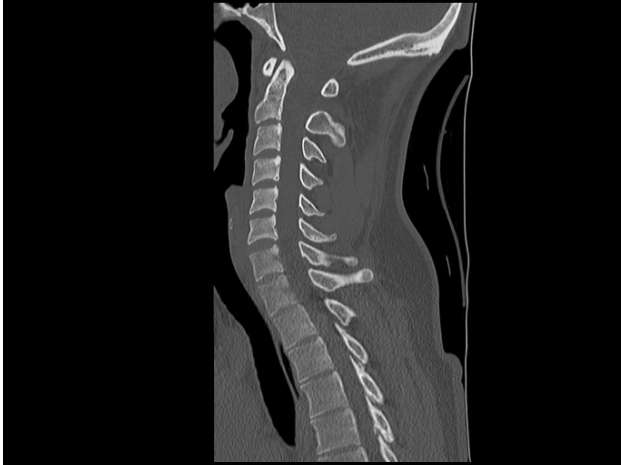
94



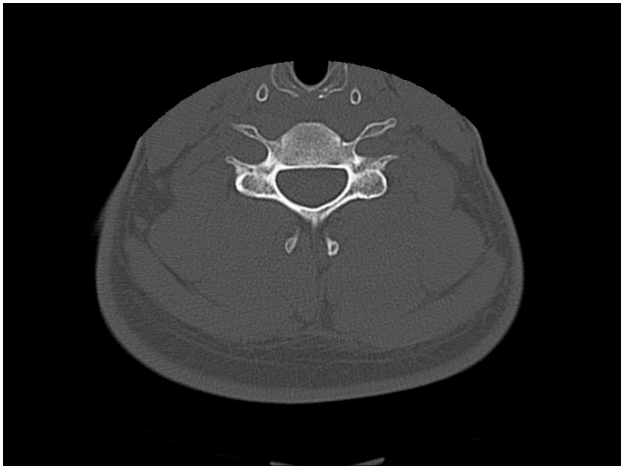
95



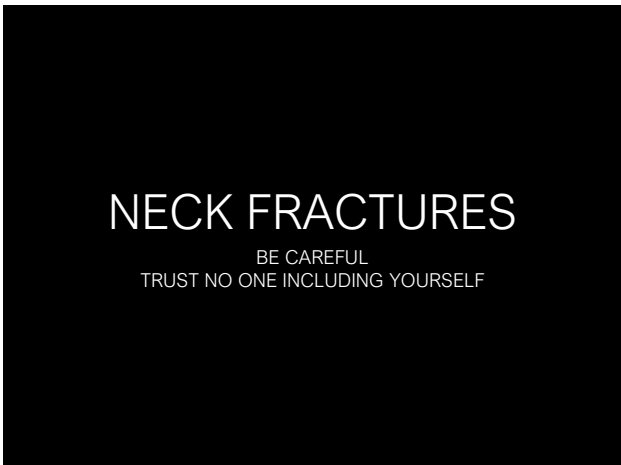96



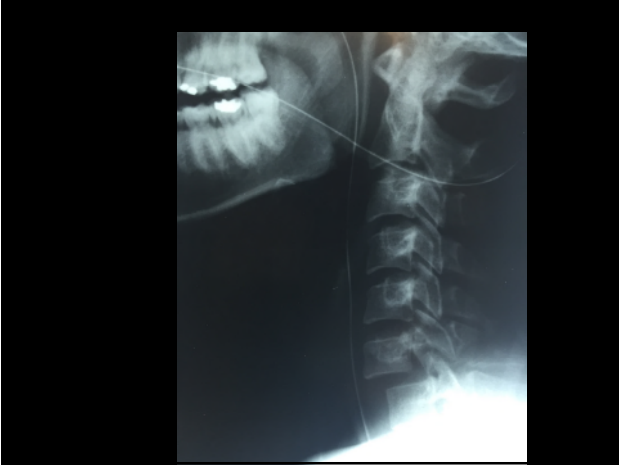97



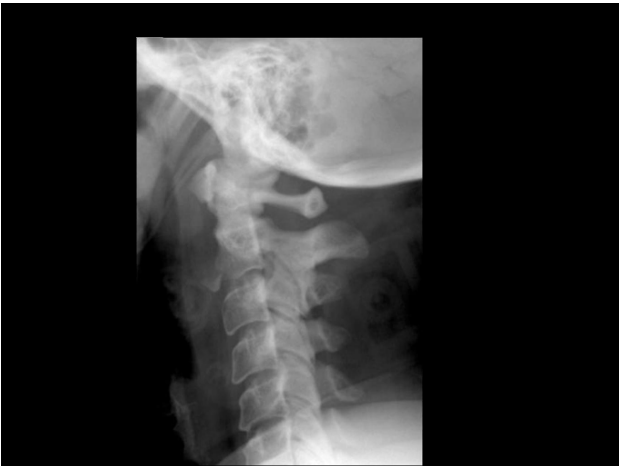98



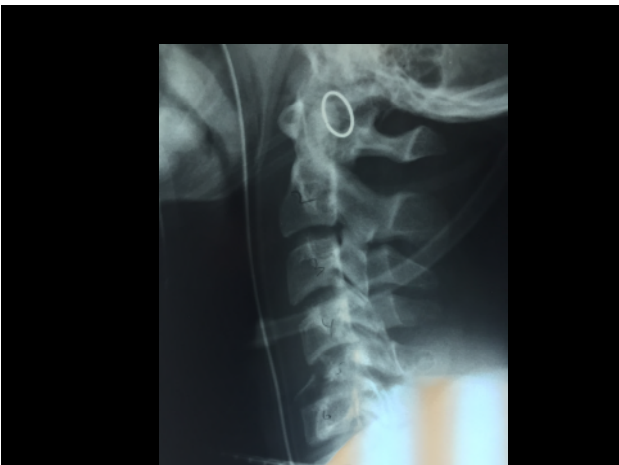99



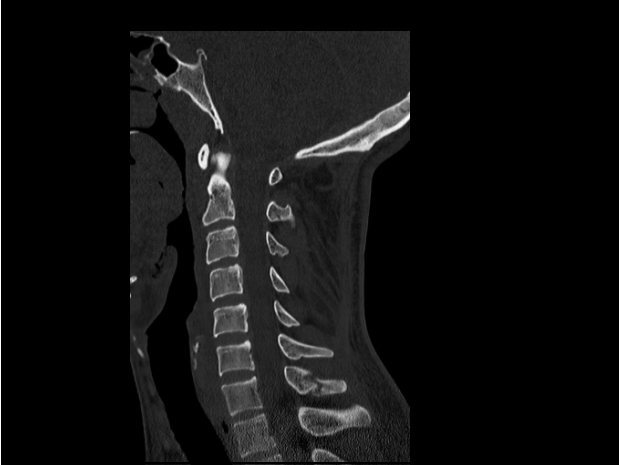100



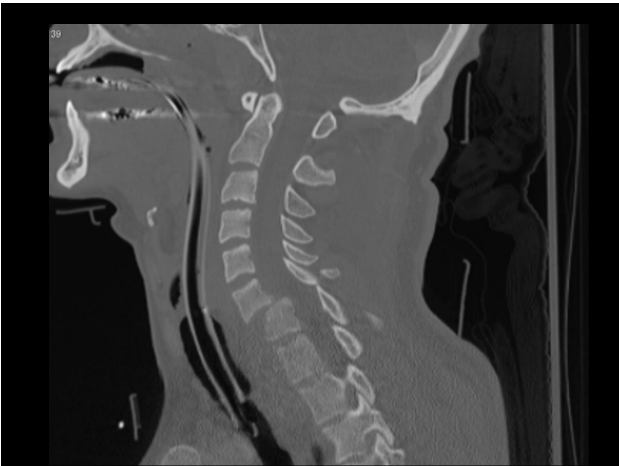101



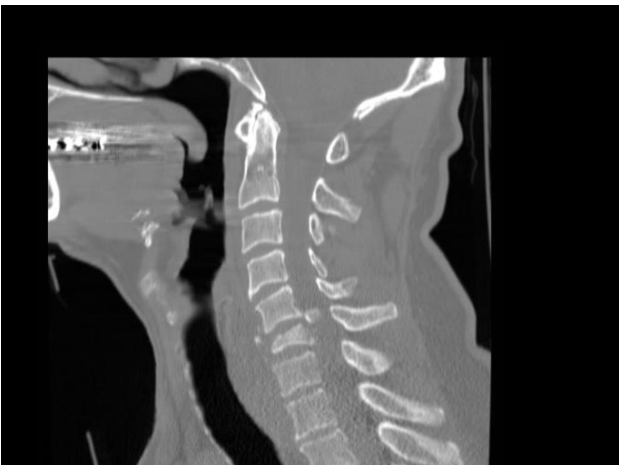102



103



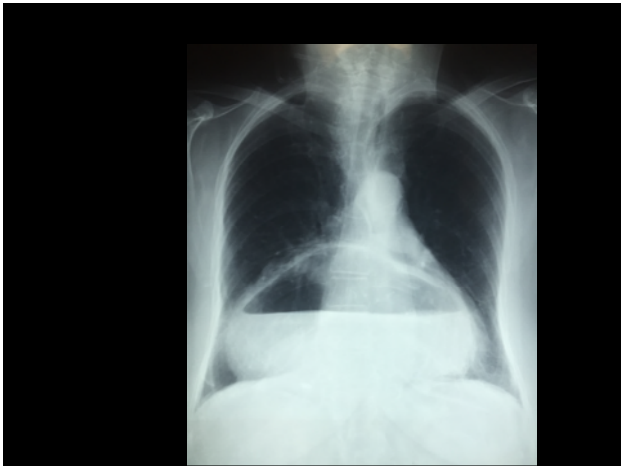104



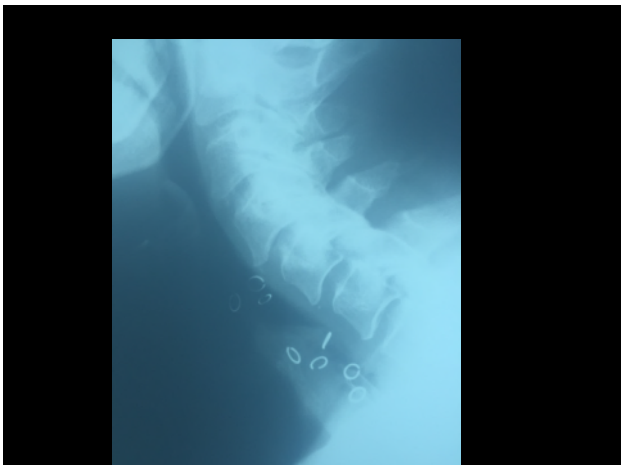
105

A FEW CASES

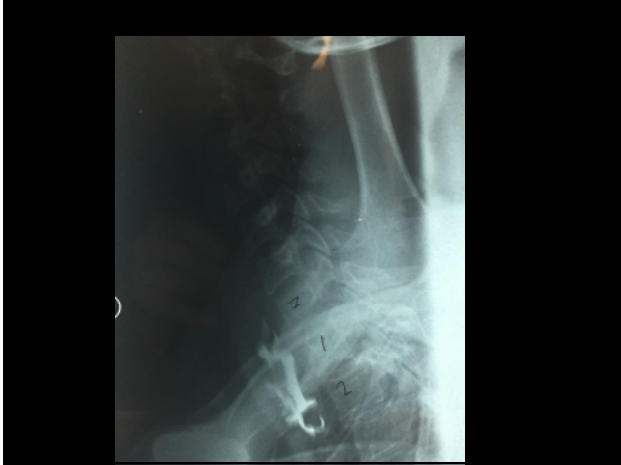106



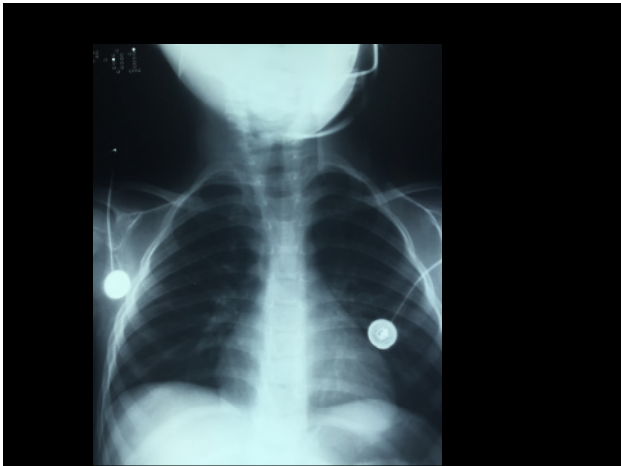
107



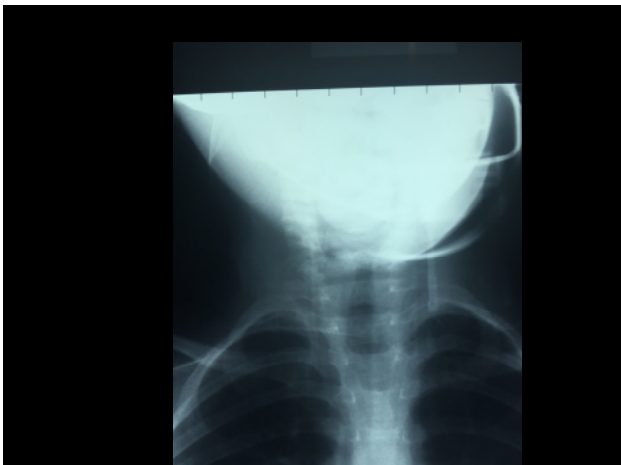
108



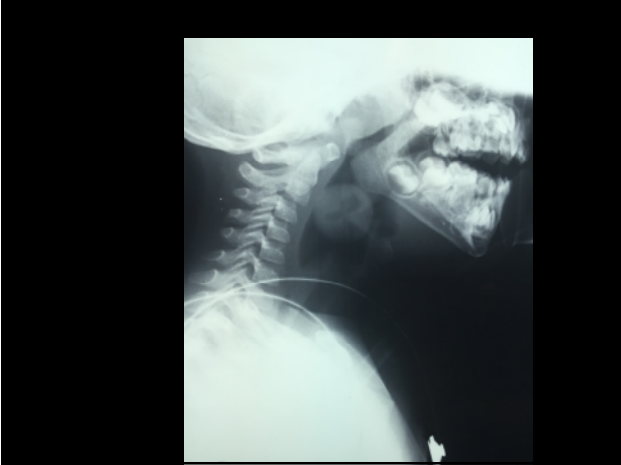
109



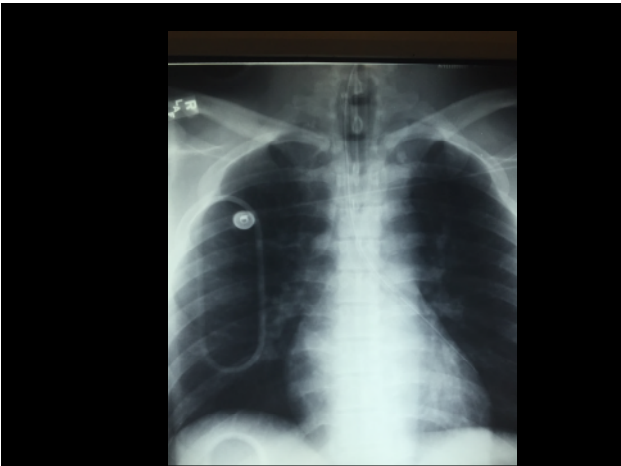
110



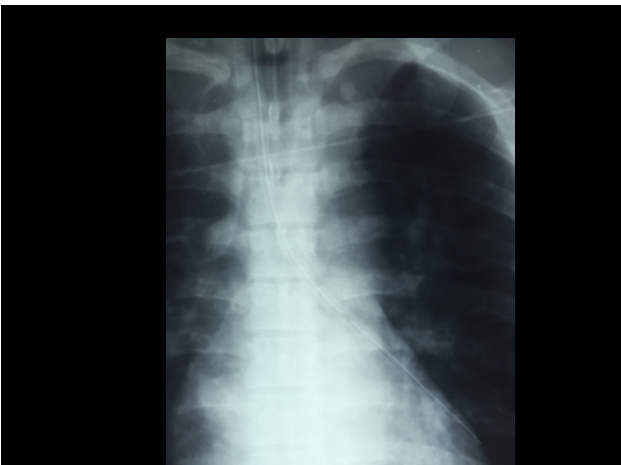111



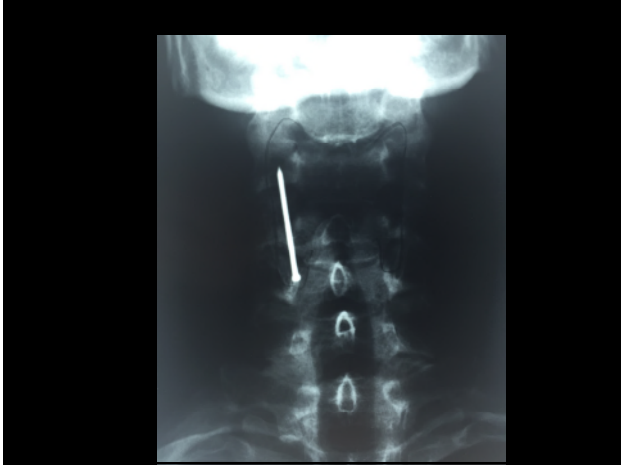112



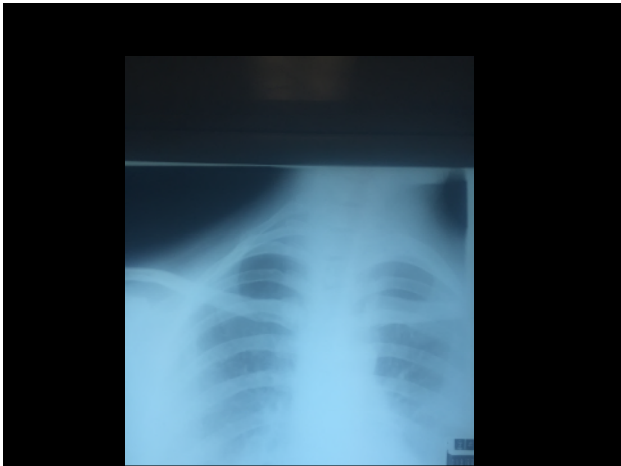113



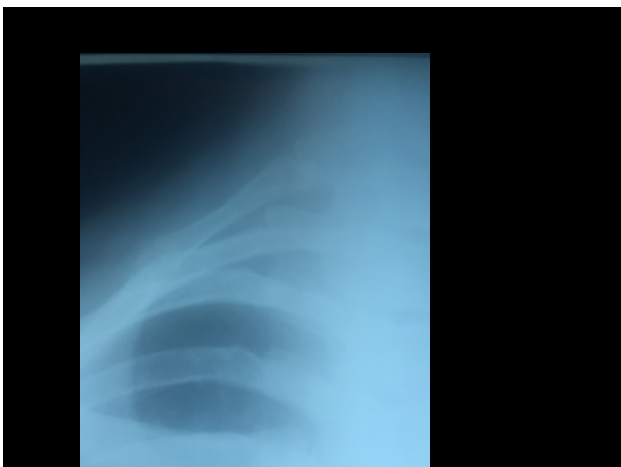
114



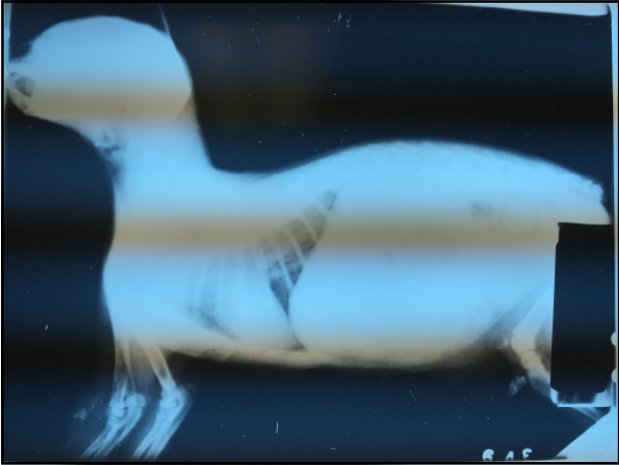
115



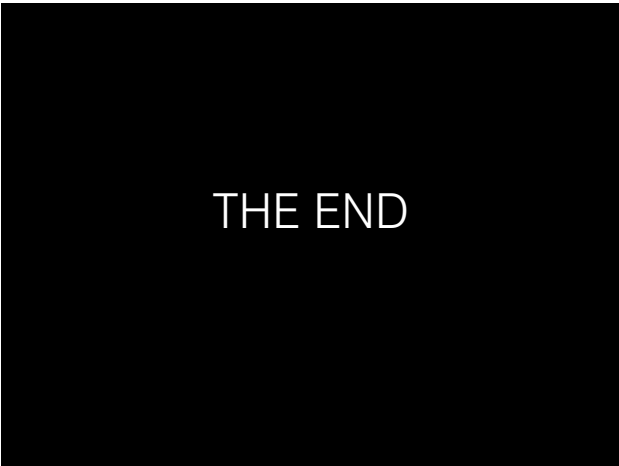116




117



118



119



120

